

Oral Cavity and Esophageal Carcinogenesis Modeled in Carcinogen-Treated Mice

Xiao-Han Tang,¹ Beatrice Knudsen,²
Debra Bemis,¹ Satish Tickoo,² and
Lorraine J. Gudas¹

Departments of ¹Pharmacology and ²Pathology, Weill Medical
College of Cornell University, New York, New York

ABSTRACT

Purpose: Squamous cell carcinoma of the oral cavity is one of the most common human neoplasms, and prevention of these carcinomas requires a better understanding of the carcinogenesis process and a model system in which cancer chemoprevention agents can be tested. We have developed a mouse model using the carcinogen 4-nitroquinoline 1-oxide (4-NQO) in the drinking water to induce tumorigenesis in the mouse oral cavity.

Experimental Design: 4-NQO was delivered by tongue painting or drinking water to two mouse strains, CBA and C57Bl/6. The incidences of oral cavity carcinogenesis were then compared. In addition, we examined the expression of some of the molecular markers associated with the process of human oral cavity and esophageal carcinogenesis, such as keratin (K) 1, K14, p16, and epidermal growth factor receptor, by immunohistochemistry.

Results: After treatment with 4-NQO in the drinking water, massive tumors were observed on the tongues of both CBA and C57Bl/6 female mice. Pathological analyses indicated that flat squamous dysplasias, exophytic papillary squamous tumors (papillomas), and invasive squamous cell carcinomas were present. Immunohistochemistry analyses showed that 4-NQO changed the expression patterns of the intermediate filament proteins K14 and K1. K14 was expressed in the epithelial suprabasal layers, in addition to the basal layer, in tongues from carcinogen-treated animals. In contrast, control animals expressed K14 only in the basal layer. Moreover, we observed more bromodeoxyuridine staining in the tongue epithelia of 4-NQO-treated mice. Reduced expression of the cell cycle inhibitor, p16, was observed, whereas 4-NQO treatment caused an increase in

epidermal growth factor receptor expression in the mouse tongues. Interestingly, similar features of carcinogenesis, including multiple, large (up to 0.5 cm) exophytic papillary squamous tumors and invasive squamous cell carcinomas, increased bromodeoxyuridine staining, and increased K14 expression, were also observed in the esophagi of 4-NQO-treated mice. However, no tumors were observed in the remainder of digestive tract (including the forestomach, intestine, and colon) or in the lungs or livers of 4-NQO-treated mice. These results indicate that this murine 4-NQO-induced oral and esophageal carcinogenesis model simulates many aspects of human oral cavity and esophageal carcinogenesis.

Conclusions: The availability of this mouse model should permit analysis of oral cavity and esophageal cancer development in various mutant and transgenic mouse strains. This model will also allow testing of cancer chemopreventive drugs in various transgenic mouse strains.

INTRODUCTION

Squamous cell carcinoma (SCC) of the oral cavity is one of the most common neoplasms in the world. Approximately 350,000 people are diagnosed annually worldwide with SCC (1). Although some primary tumors can be treated, many patients will develop second primary tumors, suggesting multifocal tumor development. Two major etiological factors in oral cavity SCC are the use of tobacco and alcohol (2). Similarly, human esophageal cancer occurs worldwide and is the eighth most prevalent cancer (3). The 5-year survival of patients diagnosed with esophageal SCC is around 30% (4). Clearly, the development of cancer chemopreventive agents for oral cavity and esophageal cancer is an important research priority (3, 5–7), and for this, animal models are needed.

Previously, several animal models for oral SCC development were generated, including hamster, rat, and mouse models. In the past, the most commonly used model was the carcinogen 7,12-dimethylbenzanthracene-induced hamster cheek pouch tumor model (8). However, as discussed by Nauta *et al.* (9) and MacDonald *et al.* (10), the 7,12-dimethylbenzanthracene-induced cheek pouch tumors are dissimilar to human oral cavity tumorigenesis in many respects. The 7,12-dimethylbenzanthracene-induced hamster cheek tumors develop during the treatment period. Thus, there is a problem in distinguishing between the transient and reversible changes of the epithelium caused by direct contact with the carcinogen and true premalignant transformation (11). Moreover, the tumors caused by 7,12-dimethylbenzanthracene do not possess many of the histological features of differentiated SCCs and do not closely resemble early human lesions (9).

Tobacco contains many carcinogens that cause carcinogenesis through the formation of DNA adducts (carcinogen-DNA adducts) in many human tissues (12). 4-Nitroquinoline 1-oxide

Received 7/7/03; revised 10/20/03; accepted 10/21/03.

Grant support: NIH Grant R01 DE10389 (to L. J. G.) and supported in part by a postdoctoral fellowship from the American Institute for Cancer Research (to X-H. T.).

The costs of publication of this article were defrayed in part by the payment of page charges. This article must therefore be hereby marked *advertisement* in accordance with 18 U.S.C. Section 1734 solely to indicate this fact.

Requests for reprints: Lorraine J. Gudas, Department of Pharmacology, Weill Medical College of Cornell University, 1300 York Avenue, New York, New York 10021. Phone: (212) 746-6250; Fax: (212) 746-8858; E-mail: ljgudas@med.cornell.edu.

(4-NQO) is a water-soluble quinoline derivative that can cause DNA adduct formation, resulting in adenosine substitution for guanosine (13–15). 4-NQO also can undergo redox cycling to produce reactive oxygen species that result in mutations and DNA strand breaks (16, 17). 4-NQO has been shown to induce oral cavity SCCs in rats (18) and mice (11, 19, 20). In the rat, the 4-NQO model has been used to test cancer chemopreventive agents (21–25). 4-NQO treatment has generally been performed by two different methods, either painting 4-NQO on mouse tongues, using a dose of 5 mg/ml (11, 19), or dissolving 4-NQO in the drinking water for rats (18, 26). Administration of 4-NQO produces a temporal carcinogenesis progression model that demonstrates multiple dysplastic, preneoplastic, and neoplastic lesions after long-term treatment (11). These sequential changes in the epithelial cells mimic human oral cavity neoplastic transformation. Additionally, 4-NQO-induced mouse oral cavity cancer is similar to human head and neck SCCs in that the expression of many genes related to tumorigenesis in humans is affected (27, 28). However, the 4-NQO tongue painting method is laborious and difficult in terms of applying the same dose from animal to animal, and the yield of tumors is relatively low (11).

Recently, a genetic mouse model of human oral-esophageal cancer was generated by overexpressing cyclin D1 in the oral-esophageal epithelium of p53-null mice (29). Whereas this model is useful to address some research questions, the overexpression of cyclin D1 may not completely reflect the multiple genetic changes that occur during the process of carcinogen-induced oral cavity carcinogenesis in humans (30, 31).

Esophageal cancer occurs worldwide. More than 90% of esophageal cancers in the world are squamous carcinomas, although adenocarcinomas are more prevalent in the United States (3). Approximately 14,000 new cases of esophageal cancer are expected to be diagnosed in 2003 (32). There is no commonly used mouse model for human esophageal SCC, although there are rat models for esophageal SCCs in which tumors are induced by a carcinogen and food contaminant, *N*-nitrosomethylbenzylamine (3, 33, 34). Compared with other animal models, mouse models of oral and esophageal SCC have obvious benefits because various transgenic and knockout lines can be examined in such models. We hypothesized that 4-NQO in the drinking water would induce carcinogenesis not only in the mouse oral cavity but also in the esophagus because the esophageal epithelium would be highly exposed to the carcinogen.

In this study, we compared 4-NQO painting of tongues and delivery of 4-NQO in the drinking water in two mouse strains and found that the latter method, at the doses of 4-NQO used, resulted in a much higher incidence of oral cavity carcinogenesis. We also showed that 4-NQO in the drinking water resulted in a high incidence of esophageal tumors. Moreover, we assessed the expression of some of the molecular markers associated with the process of human oral cavity and esophageal carcinogenesis in this model. When some of the biomarkers of human oral cavity and esophageal carcinogenesis, such as keratin (K) 1, K14, p16, and epidermal growth factor receptor (EGFR), were assayed, we found that 4-NQO induced morphological and pathological neoplastic transformations of mouse tongues and esophagi that resembled the process of tumorigen-

esis in the oral cavity and esophagus seen in humans (7, 30, 35–38).

MATERIALS AND METHODS

Animals and Carcinogen Treatment. Six-week-old female CBA and C57Bl/6 mice, purchased from The Jackson Laboratory, were used for the studies with 4-NQO. The experiments were carried out under controlled conditions with a 12-h light/dark cycle. Animals were maintained on a normal chow (Lab-diet with constant nutrition; Lab-Diet Co., Brentwood, MO). The treatments were carried out in two different ways, based in part on the work of Hawkins *et al.* (11), with modifications. The carcinogen 4-NQO (Sigma, St. Louis, MO) stock solution was prepared weekly in propylene glycol at 5 mg/ml and stored at 4°C. For the painting method, the tongues were painted with the 4-NQO stock solution three times a week, the same dose that Hawkins *et al.* (11) used. For the drinking water method, the 4-NQO stock solution was diluted in the drinking water for mice, and the water was changed once a week (see Tables 1–3 for concentrations). Mice were allowed access to the drinking water at all times during the treatment. Each strain of mice was randomly divided into an experimental group in which the drinking water contained 4-NQO and a control group in which the drinking water contained no 4-NQO, only the same volume of propylene glycol. After an 8- or 16-week carcinogen treatment, mice were analyzed for precancerous and cancerous lesions in the oral cavities and esophagi at different times for up to 12 weeks or until signs of sickness or weight loss.

Tissue Dissection and Sectioning. The tongues and esophagi of mice were dissected immediately after cervical dislocation. Mice were then subjected to autopsies; whole esophagi and stomachs were opened longitudinally, and tumors with a diameter of >1–2 mm were counted. Cross-sections of some of the tissues were cut, and tissues were fixed in freshly made 4% paraformaldehyde overnight at 4°C, embedded in paraffin, and sectioned into 5- μ m sections. Multiple sections of tissues from several mice in each treatment category were stained with various antibodies, and control sections were always stained at the same time and under the same conditions as sections from 4-NQO-treated mice.

Pathological Examination. Gross lesions were identified and photographed. The histological determination of squamous neoplasia was done by a pathologist (S. T.) on the sectioned tissue samples. The sections from the tongues and esophagi were deparaffinized, rehydrated, and stained with H&E for histopathology. The lesions observed were classified into four types: epithelial hyperplasia; dysplasia; papilloma; and invasive carcinoma. Hyperplasia was defined as thickened epithelium with prominent surface keratinization and with or without elongated rete ridges. Dysplasia was defined as loss of polarity in the epithelial cells, nuclear pleomorphism and hyperchromasia, abnormal single cell keratinization (dyskeratosis), and increased or abnormal mitoses. Lesions with such changes involving the entire thickness of epithelium were considered as carcinoma *in situ*. Papilloma was defined as noninvasive exophytic growth of neoplastic cells, and invasive carcinoma was defined as a lesion with invasion into the subepithelial tissues.

Table 1 Comparison of oral cavity carcinogenesis induced by two 4-NQO^a treatment methods and comparison of CBA and C57Bl/6 strains

The mice were treated with 4-NQO by the tongue painting method (11) or the drinking water method (26) for 16 weeks and then observed for another 12 weeks. The tongues of mice were dissected, embedded, stained with H&E or hematoxylin only, and analyzed for pathological evidence of tumors. A, comparison of the tongue painting method and the drinking water method on CBA mice; B, comparison of the tumorigenic effects of 4-NQO on the tongues of CBA and C57Bl/6 mice. Control, treatment with vehicle only (see "Materials and Methods").

A. Comparison of tongue painting and drinking water methods

Mouse strain	Method	No. of mice at week 0	No. of mice surviving at 28 weeks	4-NQO concentration	Weeks of treatment	Frequency of treatment	Incidence of papilloma	Incidence of invasive SCC
CBA	Control	10	10				0%	0%
CBA	Painting	30	30	5 mg/ml	16	3 times/week	20%	5%
CBA	Drinking water	25	20	100 µg/ml	16	<i>Ad libitum</i> in water	100%	100%

B. Tumorigenic effects of 4-NQO

Mouse strain	Method	No. of mice at week 0	No. of mice surviving at 28 weeks	4-NQO concentration	Weeks of treatment	Frequency of treatment	Incidence of papilloma ^b	Incidence of invasive SCC ^b
CBA	Control	10	10				0%	0%
CBA	4-NQO in drinking water	25	20	100 µg/ml	16	<i>Ad libitum</i> in water	100%	100%
C57 Bl/6	Control	5	5				0%	0%
C57 Bl/6	4-NQO in drinking water	10	7	100 µg/ml	16	<i>Ad libitum</i> in water	100%	100%

^a 4-NQO, 4-nitroquinoline 1-oxide; SCC, squamous cell carcinoma.

^b All mice had multiple lesions, papillomas, and carcinomas. These papillomas were on the surface and could be counted; there were 3–6 large papillomas/4-NQO-treated mouse and multiple carcinomas over the surface of the tongue.

Immunohistochemistry. The intermediate filaments and other SCC cancer markers in mouse epithelium were investigated by immunohistochemistry. The anti-cytokeratin 14 (K14, catalogue number NCL-002) antibody was obtained from Novocastra Laboratories (Newcastle, United Kingdom; Ref. 39), and anti-cytokeratin 1 (K1, catalogue number PRB-165P) antibody was from BabCo/Covance (Denver, PA). Anti-p16 (catalogue number sc-1661) and anti-EGFR (catalogue number sc-03) antibodies were from Santa Cruz Biotechnology (Santa Cruz, CA). Slides were deparaffinized and rehydrated, and antigen retrieval was performed in Antigen Unmasking Solution (Vector Laboratories, Burlingame, CA) in a pressure cooker for

2 min. After quenching endogenous peroxidase with 3% H₂O₂, the tissue sections were blocked with 1.5% goat serum or Vector special blocking reagent (when the primary antibody was mouse IgG). Then K14 (1:20) and p16 (1:200) antibodies were incubated with tissues for 30 min at 22°C, whereas K1 (1:200) and EGFR antibodies (1:200) were incubated for 1 h at 22°C, followed by incubation with secondary antibodies (1:200; anti-mouse or rabbit IgGs; Vector Laboratories). As a control, the sections were stained without incubation with primary antibody. Sections were stained by using the Vectastain Elite ABC kit (Vector Laboratories), based on a peroxidase detection mechanism (manual of the product), and 3,3'-diaminobenzidine was

Fig. 1 Morphological observations of the mouse tongues. The mice were treated with water (control) or 4-nitroquinoline 1-oxide (100 µg/ml) for 16 weeks and then observed for up to another 12 weeks. The mice were sacrificed, and the tongues were taken out at different time points of the posttreatment period. A, control; B–D, tongues with different extents of carcinogenesis. Pictures shown here are representative of CBA mice treated with carcinogen.

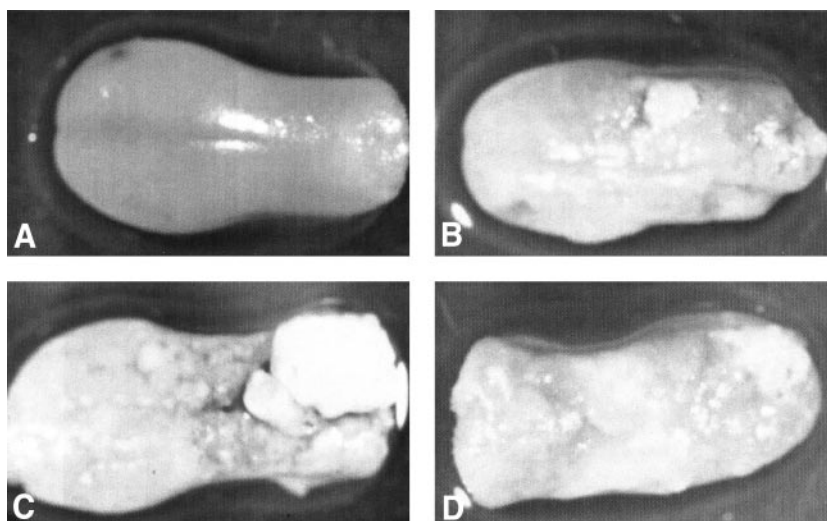


Table 2 4-NQO^a induction of esophageal tumors in CBA and C57Bl/6 mouse strains

The mice were treated with 4-NQO in drinking water for 16 weeks and then observed for another 12 weeks. The esophagi of mice were then dissected, embedded, stained with H&E, and analyzed for pathological evidence of tumors. The mice are the same groups as those shown in Table 1B.

Mouse strain	Method	No. of mice surviving at 28 weeks	4-NQO concentration	Weeks of treatment	Frequency of treatment	Incidence of hyperplasia	Incidence of papilloma	Incidence of invasive SCC
CBA	Control	10				0%	0%	0%
CBA	4-NQO in drinking water	20	100 µg/ml	16	<i>Ad libitum</i> in water	100%	100%	100%
C57 Bl/6	Control	5				0%	0%	0%
C57 Bl/6	4-NQO in drinking water	7	100 µg/ml	16	<i>Ad libitum</i> in water	100%	100%	100%

^a 4-NQO, 4-nitroquinoline 1-oxide; SCC, squamous cell carcinoma.

used as the substrate. Samples of tongues and esophagi were taken from all of the mice for sectioning; several sections from four to six mice were examined from a given treatment, and immunohistochemical staining was performed on control *versus* 4-NQO-treated tissues at the same time with the same lot and concentration of antibody to obtain semiquantitative immunohistochemical data.

Bromodeoxyuridine (BrdUrd) Labeling and Immunohistochemistry. Mice were inoculated with BrdUrd labeling reagent (catalogue number 00-0103; Zymed, South San Francisco, CA) i.p., according to the protocol of the manufacturer (1 ml/100 g body weight). After 5 h, the mice were sacrificed by cervical dislocation, and the tissues were quickly dissected, cut into cross-sections, fixed in freshly made 4% paraformaldehyde, and embedded in paraffin. The BrdUrd immunohistochemistry was carried out with a BrdUrd Detection Kit (catalogue number 93-3943; Zymed). Tissue sections were deparaffinized and rehydrated in graded ethanols. After quenching endogenous peroxidase with 3% H₂O₂, antigen retrieval was performed by digestion with trypsin for 10 min at 37°C. The DNA in tissue samples was subsequently denatured with denaturing solution from the BrdUrd Detection Kit. Tissues were then incubated with blocking solution for 30 min, followed by a 1-h incubation with biotinylated mouse monoclonal anti-BrdUrd antibody at room temperature. Slides were incubated with streptavidin-peroxidase for 10 min at room temperature. The incorporation of BrdUrd into the genomic DNA of proliferating cells was detected by staining with 3,3'-diaminobenzidine tetrahydrochloride. Finally, slides were counterstained with hematoxylin. Negative slides were not incubated with anti-BrdUrd antibody.

Cells with dark brown-stained nuclei by 3,3'-diaminobenzidine were identified as cells with BrdUrd incorporation. The BrdUrd labeling index (percentage) was determined by the number of BrdUrd-positive nuclei in a total of 300 (for tongues) or 100 (for esophagi) epithelial cell nuclei in a certain area. The data were analyzed statistically using Student's *t* test.

RESULTS

The Carcinogen 4-NQO in Drinking Water Causes Tumor Formation on Tongues and in Esophagi of Mice. We carried out several rounds of 4-NQO treatment of female CBA and C57Bl/6 mice, using different doses and durations of carcinogen treatment. We also varied the manner of 4-NQO delivery, using either tongue painting or delivery via the drinking water (Table 1).

For the 4-NQO tongue painting protocol, we followed the method of Hawkins *et al.* (11). Female CBA mice (30 mice) were treated with 4-NQO for 16 weeks. All mice survived the treatment period, and all survived the 12 posttreatment weeks. With this delivery method, 4-NQO treatment caused a much lower level of tumor formation (Table 1).

In the studies using 4-NQO in the drinking water, all control (propylene glycol only) and 4-NQO-treated CBA and C57 Bl/6 mice survived the 16-week 4-NQO (100 µg/ml) treatment, and about 80% mice survived for 12 weeks after carcinogen treatment (Table 1). No gross lesions were visible at the end of the 16-week 4-NQO treatment. We examined the tongues for lesions at different time points after carcinogen treatment and found that gross lesions developed over the following 4–12 weeks. 4-NQO exposure induced many precancerous and cancerous lesions on tongues and in esophagi of both CBA and C57Bl/6 mice. This carcinogenic process was multifocal, *i.e.*, there were several lesions at different sites on one tongue or one esophagus. At the time of sacrifice, these lesions covered almost all of the surface of the tongues; therefore, it was difficult to quantify the lesions. In the esophagi, the lesions were also multifocal. No differences in the numbers of lesions or in the severity or distribution of the lesions between the upper and lower esophagus were seen. Some of the lesions were exophytic [protruding from the surface of the tongue into the oral cavity (papillomas)], and others were endophytic [invading the deeper layers of the tongue through the basement membrane (invasive carcinomas)]. We also observed dysplasias in tongue sections from grossly nontumorous areas in the 4-NQO-treated animals, although the focus of our investigation was primarily on grossly identifiable tumor formation. The tumor incidence (papilloma and/or carcinoma) was 100% by 12 weeks after this dose (100 µg/ml) of 4-NQO treatment. Massive SCCs were observed on the dorsal sides of the tongues (Table 1, Fig. 1) and in the esophagi (Table 2) of 4-NQO-treated CBA and C57Bl/6 mice. Gross lesions were not observed in other areas of the oral cavities, most likely because of the manner in which mice drink water. The upper surface of the tongue is the region of the oral cavity that has the greatest exposure to the water.³ The palate, buccal, and floor of mouth regions

³ Dr. Hai T. Nguyen, personal communication.

Table 3 4-NQO^a dosage and duration dependence of oral cavity and esophageal tumor formation

The mice were treated with 4-NQO in drinking water for 8 or 16 weeks and then observed for another 16 or 8 weeks (total 24 weeks). The tongues and esophagi of mice were examined.

Mouse strain	Method	No. of mice at week 0	No. of mice surviving at week 24	4-NQO concentration	Weeks of treatment	Frequency of treatment	Incidence of oral cavity lesions ^b	BrdUrd labeling index of oral cavity lesions	Incidence of esophageal lesions ^b	BrdUrd labeling index of esophageal lesions
CBA	Drinking water	5	5	0	16	<i>Ad libitum</i> in water	0%	3.1 ± 1.3%	0%	0%
CBA	Drinking water	5	4	100 µg/ml	16	<i>Ad libitum</i> in water	100%	21.0 ± 0.9% ^c	100%	19.2 ± 2% ^c
CBA	Drinking water	5	4	100 µg/ml	8	<i>Ad libitum</i> in water	100%	15.1 ± 0.8% ^c	75%	15.0 ± 1.2%
CBA	Drinking water	5	3	50 µg/ml	8	<i>Ad libitum</i> in water	100%	10.9 ± 0.8% ^c	33%	0.7 ± 0.5%
CBA	Drinking water	5	5	20 µg/ml	8	<i>Ad libitum</i> in water	0% ^d	11.1 ± 0.5% ^c	0% ^d	0%

^a 4-NQO, 4-nitroquinoline 1-oxide; BrdUrd, bromodeoxyuridine; SCC, squamous cell carcinoma.

^b Lesions include papilloma, papilloma-carcinoma, and invasive squamous cell carcinoma.

^c Significant difference from control mice (0 µg/ml 4-NQO treatment), $P < 0.05$.

^d Epithelial hyperplasias and dysplasias were seen, but no papillomas or invasive squamous cell carcinomas.

were not examined in detail for hyperplasia or dysplasia, nor were molecular markers examined in these regions. Some of the mice treated with the highest dose of 4-NQO showed some body weight loss (about 5–10% of body weight), compared with the control group, at 10–12 weeks after the end of the 16-week 4NQO treatment. No gross lesions were observed in the lungs, livers, colons, or forestomachs of any of the 4NQO-treated animals. No lesions were found in the control (propylene glycol-treated) mice.

Different doses (20, 50, and 100 µg/ml) of 4-NQO in the drinking water and various lengths of 4-NQO treatment (8 and 16 weeks) were also tested. Doses of both 50 and 100 µg/ml resulted in significant lesions on the tongues; however, only the 100 µg/ml treatment for 8 or 16 weeks induced significant numbers of esophageal lesions (Table 3).

Examination of tissue sections from mice treated with 4-NQO in the drinking water at the highest dose (Tables 1 and 2) revealed pathological evidence of carcinogenesis. All tongues and esophagi from CBA and C57Bl/6 mice exhibited multiple lesions, including large (up to 0.5 × 0.5 × 0.3 cm) papillomas and/or carcinomas (Fig. 2, A–L). Tongues and esophagi from control mice showed a very clearly defined epithelium with a single layer of basal cells. 4-NQO-treated mouse tongues and esophagi showed focal increases in thickness (hyperplasia); a loss of organization of the epithelium (dysplasia/*in situ* carcinoma); exophytic, mostly papillary, neoplastic squamous lesions (papillomas); and invasive SCCs identified by the invasion of neoplastic epithelial cells into the subepithelial tissues (Fig. 2, A–L).

4-NQO Induced Alterations in K14 and K1 Expression in Mouse Tongues and Esophageal Epithelia during Carcinogenesis. Keratins belong to the family of the intermediate filaments in epithelial cells. There are about 30 different keratins, with different cell type- and differentiation-specific expression patterns (40). The keratin genes expressed in mouse soft epithelia are K1–K20 (41). Keratins K5 and K14 are expressed in the proliferating basal layer cells,

whereas keratins K1 and K10 are expressed in the suprabasal layers of many types of epithelia (42). Evidence that keratin alterations are related to oral cavity and esophageal carcinogenesis has been accumulating. Kannan *et al.* (43) discovered a correlation between the expression levels of K10/K11, K19, and K14 and the stages of tumorigenesis of oral mucosa. The studies of Cintonaro *et al.* (44) and Fong *et al.* (39) demonstrated that increased K14 is a biomarker in human and mouse esophageal carcinogenesis. In addition, high K14 expression throughout the epithelium was found in the majority of cases of human SCC, regardless of origin or degree of differentiation (45).

Immunohistochemical analyses showed that the expression pattern of K14 was altered in mouse tongue epithelia by 4-NQO delivered via the drinking water (Fig. 3A). In CBA mice, after treatment with 4-NQO, K14 was expressed in the suprabasal layers in addition to the basal layer of the tongues. In contrast, the control mice exhibited K14 expression only in the basal layer. The expression pattern of K14 was altered after 4-NQO treatment not only in the sections of carcinoma, but also before the grossly visible lesions appeared (Fig. 3A).

Esophageal epithelia of 4-NQO-treated CBA mice were much thicker than those of control mice. The lumens of the esophagi became very narrow. The expression of K14 was also changed in the esophageal epithelia of CBA mice treated with 4-NQO; K14 staining was found in both basal and suprabasal layers, whereas in control mice, K14 was only clearly detected in the basal layer (Fig. 3A). Additionally, the results from different doses and different durations of 4-NQO treatment showed that 50 and 100 µg/ml 4-NQO caused a dramatic increase in the level and area of the expression of K14 in the mouse tongues and esophageal epithelia. Only the lowest dose (20 µg/ml 4-NQO for 8 weeks) did not induce such changes in K14 (Fig. 3B).

Aberrant expression of K1 has been observed in precancerous lesions of the human oral cavity (46). 4-NQO treatment resulted in

an increase in the level of cytokeratin 1 (K1) expression and an expansion in the area of expression in mouse tongue epithelium (Fig. 3C). Similar to the 4-NQO induced changes in K14 expression level in mouse esophagi, K1 expression was elevated in the epithelia of esophagi (Fig. 3C). Both CBA and C57Bl/6 mice showed similar changes in K1 and K14 expression in tongues and esophagi after 4-NQO treatment (data not shown).

The Expression of p16 Was Decreased in the Epithelia of Mouse Tongues and Esophagi after 4-NQO Treatment. During the process of carcinogenesis, the dysregulation of the cell cycle is a critical event. Several mitogenic signals activate cyclin D and related cyclin-dependent kinase (CDK) complexes and induce cells to pass the G₁-S-phase transition and enter S phase (47). One of cell cycle inhibitors is p16, also known as *MTS-1* (major tumor suppressor 1), which inhibits CDK4/6. The binding of p16 results in the release of cyclin D1 from CDK4 and CDK6 and its subsequent degradation (48–50). *p16* is a target commonly involved in esophageal carcinogenesis (51), and the abrogation of p16 occurs frequently in human oral cancers (52). The loss of expression of p16 has been observed in oral premalignant lesions (53, 54), primary tumors of the oral cavity (55–58), and squamous carcinomas of the upper aerodigestive tract (59).

Therefore, the expression of the CDK inhibitor p16 in the epithelia of tongues and esophagi was investigated. In control CBA mice, most nuclei that stained with anti-p16 antibody were in the basal and suprabasal layers of mouse tongue epithelium (Fig. 4A). In the sections from 4-NQO-treated CBA mice, the morphology of the epithelium was altered, and the number of p16-stained nuclei decreased, particularly in the tumors (Fig. 4B). Additionally, p16-stained nuclei were detected in the well-organized basal and suprabasal layers of esophagi in control CBA mice, whereas very few p16-positive nuclei were observed in the thickened esophageal epithelium of 4-NQO-treated mice (Fig. 4, *C versus D*).

In addition to the CBA mice, we examined the changes in expression patterns of p16 in the epithelia of mouse tongues and esophagi of C57Bl/6 mice after 4-NQO treatment. 4-NQO caused very similar changes in the expression patterns of p16 in the tongue and esophageal epithelia of these mice (data not shown).

EGFR Protein Staining Increased in the Dysplastic Lesions and Tumors in Mouse Tongues and Esophagi. The EGFR is a transmembrane protein with an intracellular tyrosine kinase domain that regulates cell growth when bound to its ligands, epidermal growth factor (60) or transformation growth factor α (61). The EGFR is overexpressed in many types of cancer, including stomach, breast, and brain tumors (62, 63), and therapies have been designed to target the EGFR (64, 65). Overexpression of the EGFR in head and neck SCC (66–71) and esophageal SCC (72) has also been described.

We examined the EGFR levels in the epithelia of tongues and esophagi in control and 4-NQO-treated CBA mice. Samples from 4-NQO-treated mice demonstrated that hyperplasias in mouse tongue epithelia displayed elevated EGFR levels, compared with the samples from control mice (Fig. 4, *G and H*). In control mice, the EGFR was expressed primarily in the basal layer of the tongue epithelium, whereas in 4-NQO-treated mice, the expression of the EGFR was seen

throughout the entire thickness of hyperplastic epithelium. In addition, the levels of EGFR were higher in sections of carcinoma than in sections from mild hyperplasia (data not shown). These data are similar to the observations in human head and neck cancer (69).

The esophageal epithelia of CBA mice showed higher EGFR levels and expanded regions of EGFR expression after 4-NQO treatment than control esophageal epithelia (Fig. 4, *I and J*). In the esophageal epithelia of 4-NQO-treated mice, the normal regions adjacent to the tumor areas did not display the increase in level and the expansion of EGFR expression (data not shown).

We also assayed for the effects of 4-NQO on the expression of the EGFR in the epithelia of tongues and esophagi of C57Bl/6 mice. C57Bl/6 mice also showed increased areas of EGFR expression in the esophageal epithelia after 4-NQO treatment (data not shown).

4-NQO Enhanced Cell Proliferation in the Epithelia of Mouse Tongues and Esophagi. The incorporation of BrdUrd (a thymidine analog) into the DNA is used as an index of cells in S phase (73). Compared with the tongue epithelia of control CBA mice, the number of BrdUrd-labeled cells was greatly increased in the tongue epithelia of 4-NQO-treated mice. Moreover, the BrdUrd-stained nuclei were present not only in the basal layer, but some staining was also observed in the suprabasal layers (Fig. 5A; see Table 3 for quantitative data).

All doses of 4-NQO caused an increase in the BrdUrd labeling in the mouse tongue epithelia, despite the fact that 20 μ g/ml 4-NQO for 8 weeks did not induce obvious gross cancerous lesions (Fig. 5B; Table 3). Moreover, with increasing doses and durations of 4-NQO treatment, the BrdUrd-stained nuclei were present in both the basal and suprabasal layers of epithelia of the tongues and throughout the tumor tissue (Fig. 5B, *a versus d and e*).

In esophagi, 20 μ g/ml 4-NQO did not cause an increase in BrdUrd staining. 4-NQO at 50 μ g/ml for 8 weeks caused esophageal lesions only in one of three mice, and this treatment regimen slightly increased the incorporation of BrdUrd. Only the 8-week and 16-week treatments with 100 μ g/ml 4-NQO caused significant increases in BrdUrd incorporation in the esophageal epithelia, and both treatments resulted in large tumorigenic lesions in mouse esophageal epithelia (Fig. 5, *A and B*; Table 3).

DISCUSSION

Carcinogenesis Induced by 4-NQO in Drinking Water in Mouse Tongue and Esophageal Epithelia. Hawkins *et al.* (11) and Steidler *et al.* (19) reported that painting 4-NQO on mouse tongues could induce oral cavity SCC. However, only a low incidence of SCC was seen by Hawkins *et al.* (11). Steidler *et al.* (19) observed that all animals that received 4-NQO for 16 weeks by painting 3 \times /week developed SCCs, but not until 50 weeks. Our current study demonstrates that 4-NQO in the drinking water causes premalignant and malignant lesions in the oral cavities, particularly in the tongues, and in the esophagi of mice as well. Furthermore, the incidence of carcinogenesis is higher when 4-NQO is delivered in the drinking water than when

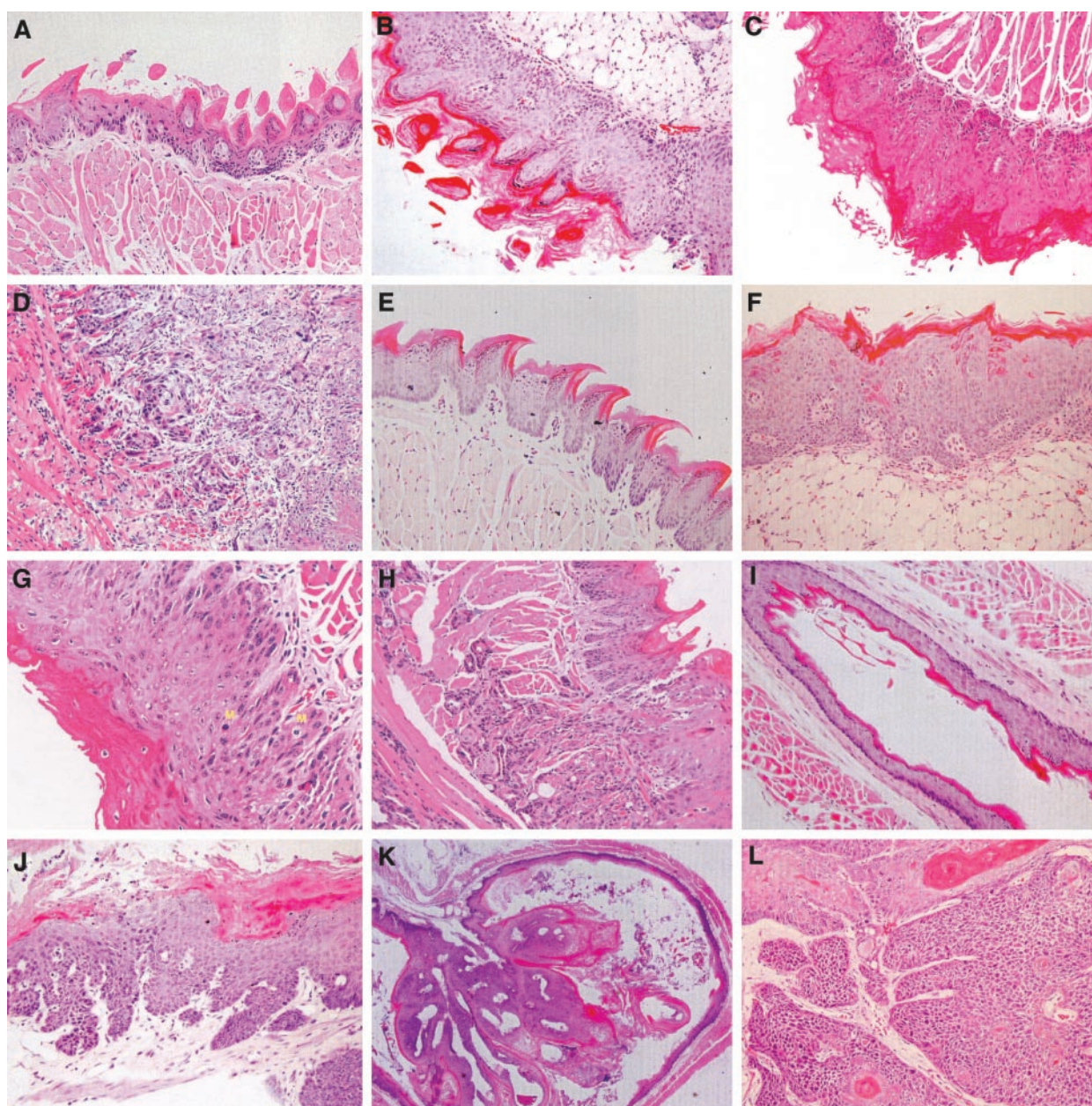


Fig. 2 Pathological evidence of carcinogenesis in CBA mouse tongues after carcinogen treatment. The mice were treated with vehicle (propylene glycol, control) or 4-nitroquinoline 1-oxide (100 $\mu\text{g}/\text{ml}$) in drinking water (see "Materials and Methods") for 16 weeks and then maintained for another 12 weeks. The mice were sacrificed, and the tongues were fixed, embedded, sectioned, and stained with H&E. **A**, normal squamous epithelium of the tongue of a control CBA mouse. **B**, hyperplasia with marked hyperkeratosis. **C**, dysplasia (low grade) with nuclear pleomorphism and mild cytologic disorganization. **D**, invasive SCC with tumor cells invading the skeletal muscle fibers of the tongue. Pathological evidence of carcinogenesis in C57Bl/6 mouse tongues after carcinogen treatment. **E**, normal squamous epithelium of the tongue of a control C57Bl/6 mouse. **F**, hyperplasia in a tongue. **G**, dysplasia (high grade)/carcinoma *in situ* showing marked nuclear atypia and increased mitotic activity (*M*), involving the full thickness of the epithelium. **H**, invasive SCC deeply invading into the skeletal muscle fibers of the tongue. Pathological evidence of carcinogenesis in mouse esophagi after carcinogen treatment. **I**, normal epithelium of a CBA mouse esophagus. **J**, markedly hyperplastic epithelium with dysplasia of the esophagus of a C57Bl/6 mouse. **K**, exophytic papillary tumor (papilloma) almost completely filling the esophageal lumen in a CBA mouse esophagus. **L**, invasive SCC in a C57Bl/6 mouse esophagus ($\times 400$).

4-NQO is painted on the tongues (Table 1). Delivery of the 4-NQO in the drinking water at the doses we used was associated with a carcinogenic process that occurred more rapidly than that observed by Steidler *et al.* (19). We observed that 100% of

the mice exhibited tongue or esophageal neoplasms at the highest 4-NQO doses by 24–28 weeks after the start of the experiment (Tables 1–3).

The mouse tongues did not exhibit any gross abnormal

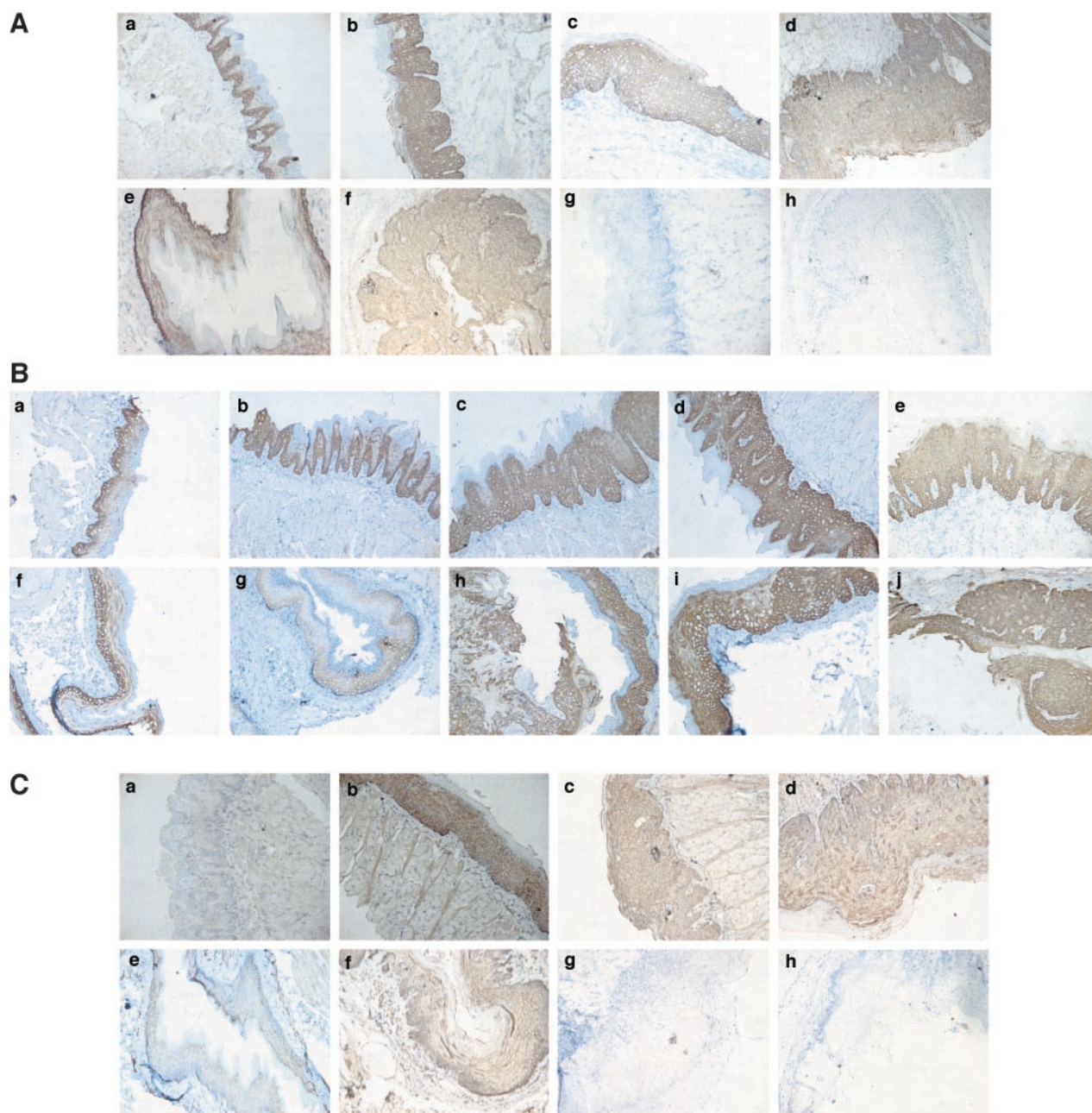
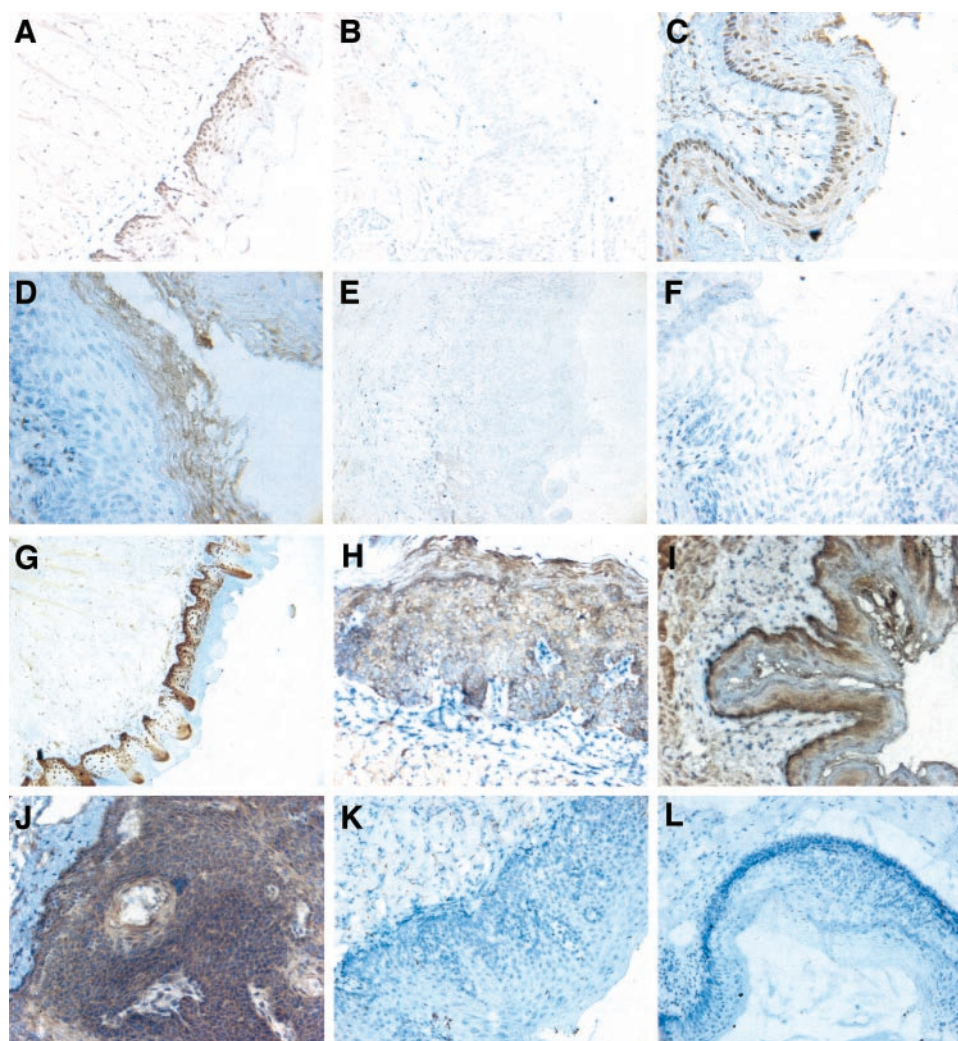


Fig. 3 A, expression of keratin (K) 14 in CBA mouse tongues and esophagi ($\times 200$). The mice were treated with vehicle (control) or 4-nitroquinoline 1-oxide (4-NQO; 100 $\mu\text{g}/\text{ml}$) in water for 16 weeks and then maintained for another 12 weeks. The mice were sacrificed, and the tongues and esophagi were fixed, embedded, sectioned, and stained with anti-K14 antibody (1:20). *a*–*d*, K14 in mouse tongues. *a*, control tongue. *b*–*d*, tongues with different extents of hyperplasia induced by 4-NQO. *e*, control mouse esophagus. *f*, hyperplasia in 4-NQO-treated mouse esophagus. *g* and *h*, negative controls. 4-NQO-treated (*g*) tongue and (*h*) esophagus stained only with secondary antibody. B, expression of K14 in CBA mouse tongues and esophagi after different doses and durations of 4-NQO treatment ($\times 200$). The mice were treated with vehicle (control) or 4-NQO in water for 8 or 16 weeks and then maintained for another 8 or 16 weeks. The mice were sacrificed, and the tongues and esophagi were fixed, embedded, sectioned, and stained with anti-K14 antibody. *a*–*e*, K14 in tongues. *a*, control. *b*, 20 $\mu\text{g}/\text{ml}$ 4-NQO for 8 weeks. *c*, 50 $\mu\text{g}/\text{ml}$ 4-NQO for 8 weeks. *d*, 100 $\mu\text{g}/\text{ml}$ 4-NQO for 8 weeks. *e*, 100 $\mu\text{g}/\text{ml}$ 4-NQO for 16 weeks. *f*–*j*, K14 in esophagi. *f*, control. *g*, 20 $\mu\text{g}/\text{ml}$ 4-NQO for 8 weeks. *h*, 50 $\mu\text{g}/\text{ml}$ 4-NQO for 8 weeks. *i*, 100 $\mu\text{g}/\text{ml}$ 4-NQO for 8 weeks. *j*, 100 $\mu\text{g}/\text{ml}$ 4-NQO for 16 weeks. C, expression of K1 in CBA mouse tongues and esophagi ($\times 200$). The mice were treated with vehicle (control) or 4-NQO (100 $\mu\text{g}/\text{ml}$) in the drinking water for 16 weeks and then maintained for another 12 weeks. The mice were sacrificed, and the tongues and esophagi were fixed, embedded, sectioned, and stained with anti-K1 antibody (1:200). *a*–*d*, K1 in mouse tongues; *e*–*h*, K1 in mouse esophagi. *a*, control mouse tongue. *b*–*d*, tongues with different extents of carcinogenesis induced by 4-NQO. *e*, control mouse esophagus. *f*, 4-NQO-treated mouse esophagus. *g* and *h*, negative controls, 4-NQO-treated tongue (*g*) and esophagus (*h*) stained only with secondary antibody.

Fig. 4 Expression of p16 in CBA mouse tongues and esophagi. The mice were treated with vehicle (control) or 4-nitroquinoline 1-oxide (4-NQO; 100 μ g/ml) in the drinking water for 16 weeks and then maintained for another 12 weeks. The mice were sacrificed, and the tongues and esophagi were fixed, embedded, sectioned, and stained with anti-p16 antibody (1:200). **A**, control tongue ($\times 200$). **B**, 4-NQO-treated tongue ($\times 200$). **C**, control esophagus ($\times 400$). **D**, 4-NQO-treated esophagus ($\times 600$). **E** and **F**, negative controls: 4-NQO-treated tongue (**E**; $\times 200$) and esophagus (**F**; $\times 400$) stained only with secondary antibody. Expression of EGFR in CBA mouse tongues and esophagi ($\times 200$). The mice were treated with vehicle (control) or 4-NQO (100 μ g/ml) in the drinking water for 16 weeks and then maintained for another 12 weeks. The mice were sacrificed, and the tongues and esophagi were fixed, embedded, sectioned, and stained with anti-EGFR antibody (1:200). **G**, control tongue. **H**, 4-NQO-treated tongue. **I**, control esophagus. **J**, SCC in 4-NQO-treated esophagus. **K** and **L**, negative controls: 4-NQO-treated tongue (**K**) and 4-NQO-treated esophagus (**L**) stained only with secondary antibody.



morphological changes in the epithelia or inflammation during the 4-NQO treatment, and the neoplastic lesions developed over time after the 4-NQO treatment was completed. These results indicate that in this model, we can eliminate the possibility that the premalignant lesions observed are transient and regress when the carcinogen is removed. Because 4-NQO is a carcinogen that induces mutagenesis (74), the morphological changes and the precancerous and cancerous lesions in mouse tongues that develop after the period of 4-NQO treatment most likely result from the accumulation of genetic mutations. The lesions progressed over time after 4-NQO treatment, from hyperplasia, dysplasia, and papilloma to invasive carcinoma. In the esophagus we noted squamous carcinomas and not adenocarcinomas. Our data demonstrate that the mouse model we have developed is a useful model for the analysis of both oral cavity and esophageal squamous carcinogenesis.

Tanuma *et al.* (18) and Tanaka *et al.* (26) observed that 20 μ g/ml 4-NQO in drinking water induced SCC in rat oral cavities. They treated rats with 4-NQO for 8 weeks and then maintained these rats for another 22–24 weeks (30–32 weeks total)

after stopping the treatment. In our study, we treated mice with 20, 50, and 100 μ g/ml 4-NQO in drinking water for 8 weeks, and after another 16 weeks, the 50 and 100 μ g/ml 4-NQO treatments caused large lesions in mouse tongues, whereas the 20 μ g/ml dose did not. Similar to our results, Ide *et al.* (75) reported that a low dose of 4-NQO (0.001%, *i.e.*, 10 μ g/ml for 50 weeks) did not induce tumors on wild-type mouse tongues. However, it is possible that after a longer time period, lesions would have been seen in the mice we dosed with 4-NQO at 20 μ g/ml for 8 weeks because we did observe some changes at the molecular level, such as an increased BrdUrd labeling index in tongues from these mice. Thus, our findings are in many respects similar to those reported for rats given 4-NQO in their drinking water, although we examined our 4-NQO-treated mice at 24 weeks, whereas the rats were analyzed at 30–32 weeks.

After 4-NQO treatment, not only the tongues but also the esophagi of mice exhibited signs of neoplastic transformation. Interestingly, no visible, gross lesions or carcinomas were found in the stomach, intestine, or colon. Although they did not assay for carcinogenesis, von Pressentin *et al.* (76) reported that a

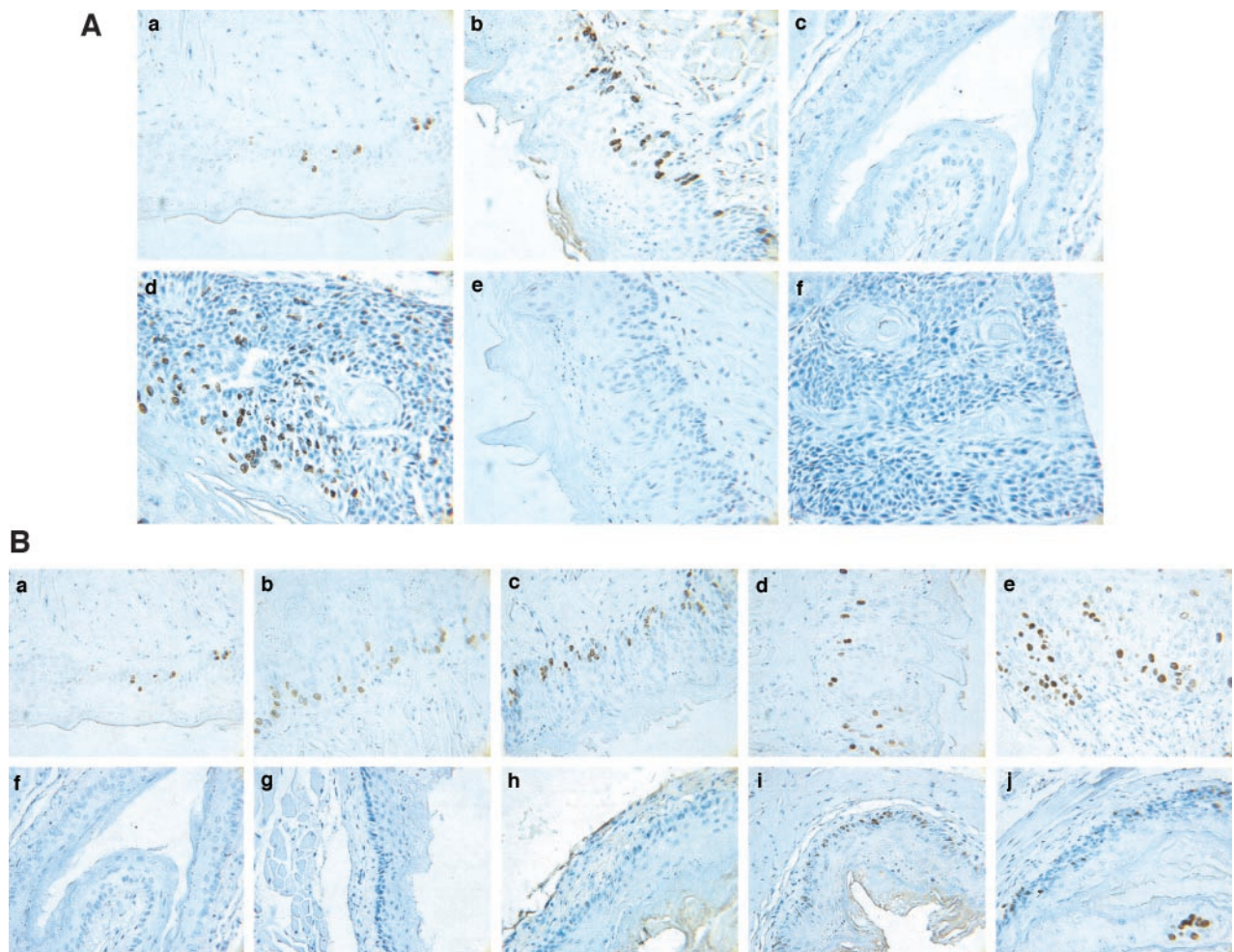


Fig. 5 A, bromodeoxyuridine (BrdUrd)-stained nuclei in CBA mouse tongues and esophagi ($\times 600$). The mice were treated with vehicle (control) or 4-nitroquinoline 1-oxide (4-NQO; $100 \mu\text{g/ml}$) in the drinking water for 16 weeks and then maintained for another 12 weeks. Before sacrifice, the mice were inoculated with BrdUrd as described in "Materials and Methods." The mice were sacrificed, and the tongues and esophagi were fixed, embedded, sectioned, and stained with anti-BrdUrd antibody. *a*, control tongue. *b*, 4-NQO-treated tongue. *c*, control esophagus. *d*, 4-NQO-induced esophageal SCC. *e* and *f*, negative controls: 4-NQO-treated tongue (*e*) and esophagus (*f*) stained without anti-BrdUrd antibody. B, BrdUrd-stained nuclei in CBA mouse tongues and esophagi after different doses and durations of 4-NQO treatment ($\times 600$). The mice were treated with vehicle (control) or 4-NQO in the drinking water for 8 or 16 weeks and then maintained for another 8 or 16 weeks. The mice were inoculated with BrdUrd and sacrificed, and the tongues and esophagi were fixed, embedded, sectioned, and stained with anti-BrdUrd antibody. *a*–*e*, BrdUrd labeling in tongue samples. *a*, control. *b*, $20 \mu\text{g/ml}$ 4-NQO for 8 weeks. *c*, $50 \mu\text{g/ml}$ 4-NQO for 8 weeks. *d*, $100 \mu\text{g/ml}$ 4-NQO for 8 weeks. *e*, $100 \mu\text{g/ml}$ 4-NQO for 16 weeks. *f*–*j*, BrdUrd labeling in esophageal samples. *f*, control; *g*, $20 \mu\text{g/ml}$ 4-NQO for 8 weeks; *h*, $50 \mu\text{g/ml}$ 4-NQO for 8 weeks; *i*, $100 \mu\text{g/ml}$ 4-NQO for 8 weeks; *j*, $100 \mu\text{g/ml}$ 4-NQO for 16 weeks.

2-week 4-NQO treatment ($20 \mu\text{g/ml}$ in the drinking water) caused mutagenesis in mouse tongues and esophagi, but not in colon.

4-NQO Induced the Expression of Cytokeratin Proteins in the Epithelia of Mouse Tongues and Esophagi. Keratins, such as K1 (46), K14 (39, 43, 44), and K19 (77), have been used as biomarkers of SCCs. In normal squamous epithelia, the single layer of basal cells expresses K5 and K14; when these cells move upward into the suprabasal layers, they switch their keratin expression to K1 and K10 (42). In our studies, 4-NQO caused an increase in the level and an expansion in the regions of expression of K14 in the mouse tongues and esophagi, which is consistent with the reports of Cintorino *et al.* (44), Kannan *et al.* (43), Viaene *et al.* (78), and Fong *et al.* (39) that K14 was present in SCCs. In addition, the expression of K1 was also increased in the epithelia of mouse tongues and esophagi; this result is also similar to a previous study of human samples (46).

The Effects of 4-NQO on Cell Growth and Cell Cycle Regulators in Mouse Tongue and Esophageal Epithelia. We investigated the level of cell proliferation in the epithelia of mouse tongues and esophagi by using BrdUrd and p16 antibodies. BrdUrd, a thymidine analog, can be incorporated into DNA in the S phase of cell cycle. Hence, the cells that traversed S phase can be detected with an anti-BrdUrd antibody. After 4-NQO treatment, the mouse tongue and esophageal epithelia showed a greater number of BrdUrd-stained cells than the

tongue and esophageal epithelia of control mice (Table 3; Fig. 5). Also, analyses of different doses and durations of 4-NQO showed that 20 μ g/ml 4-NQO for 8 weeks increased the incorporation of BrdUrd into the DNA of epithelial cells, even though there were no obvious lesions in the mouse tongues. This suggests that 4-NQO results in increases in cell proliferation in mouse tongues that are related to the process of carcinogenesis.

p16 is a member of a group of CDK inhibitors (48). Previous studies reported p16 protein inactivation, resulting from either gene deletion or promoter methylation, in oral cancers (79), esophageal squamous carcinomas (51), upper aerodigestive tract (59), and head and neck squamous carcinomas (80). In control mice, most p16-stained cells were in the basal layer of the tongue epithelium, whereas in invasive carcinomas of the tongue, only a few cells showed p16 staining (Fig. 4). These results agree with the previous studies described above.

4-NQO Treatment Resulted in Increased Expression of the EGFR in Mouse Tongues and Esophageal Epithelia.

Evidence has accumulated that an increase in expression of EGFR family members is involved in human head and neck cancer (Refs. 67 and 69–71; for review, see Ref. 30). Thus, inhibition of EGFR expression or activity could result in the suppression of head and neck cancer cell growth (81–83). Uhlman *et al.* (84) reported that laryngeal epithelial lesions with higher EGFR expression levels were more likely to progress to invasive cancer as compared with the epithelial lesions with lower levels of EGFR staining. We found that with 4-NQO treatment, the intensity of EGFR staining in the epithelia of mouse tongues and esophagi increased during the process of carcinogenesis (Fig. 4). Our findings suggest that, similar to what is observed in humans, an increase in EGFR protein expression is a marker of carcinogenesis induced by 4-NQO.

Taken together, our data indicate that this new mouse model of 4-NQO-induced oral and esophageal cancer is a useful model in that it mimics many features and molecular events observed human SCC development. This model should be advantageous for studies of oral and esophageal cancer development. Moreover, it should also be useful for cancer chemoprevention studies in a variety of mutant and transgenic mouse strains.

ACKNOWLEDGMENTS

We appreciate the insightful scientific input provided by the members of the Gudas laboratory.

REFERENCES

- Parkin, S. M., Pisani, P., and Ferlay, J. Estimates of worldwide incidence of eighteen major cancers. *Int. J. Cancer*, 54: 594–606, 1993.
- Binnie, W. H., Rankin, K. V., and Mackenzie, I. C. Etiology of oral squamous cell carcinoma. *J. Oral Pathol.*, 12: 11–29, 1983.
- Stoner, G. D., and Gupta, A. Etiology and chemoprevention of esophageal squamous cell carcinoma. *Carcinogenesis (Lond.)*, 22: 1737–1746, 2001.
- Estes, N. C., Stauffer, J., Romberg, M., Thomas, J. H., Jewell, W. R., and Hermreck, A. Squamous cell carcinoma of the esophagus. *Am. Surg.*, 62: 573–576, 1996.
- Hong, W. K., and Sporn, M. B. Recent advances in chemoprevention of cancer. *Science (Wash. DC)*, 278: 1073–1077, 1997.
- Khuri, F. R., Lippman, S. M., Spitz, M. R., Lotan, R., and Hong, W. K. Molecular epidemiology and retinoid chemoprevention of head and neck cancer. *J. Natl. Cancer Inst. (Bethesda)*, 83: 199–211, 1997.
- Kim, E. S., Hong, W. K., and Khuri, F. R. Chemoprevention of aerodigestive tract cancers. *Annu. Rev. Med.*, 53: 223–243, 2002.
- Baker, S. Malignant neoplasms of the oral cavity. In: C. W. Cummings, J. M. Fredrickson, L. A. Harker, C. J. Krause, and D. E. Schuller (eds.), *Otolaryngology-Head and Neck Surgery*, pp. 1281–1343. St. Louis, MO: CV Mosby, 1986.
- Nauta, J. M., Roodenburg, J. L., Nikkels, P. G., Witjes, M. J., and Vermey, A. Comparison of epithelial dysplasia: the 4NQO rat palate model and human oral mucosa. *Int. J. Oral Maxillofac. Surg.*, 24: 53–58, 1995.
- MacDonald, D. G. Comparison of epithelial dysplasia in hamster cheek pouch carcinogenesis and human oral mucosa. *J. Oral Pathol.*, 10: 186–191, 1981.
- Hawkins, B. L., Heniford, B., Ackermann, D. M., Leonberger, M., Martinez, S. A., and Hendler, F. J. 4NQO carcinogenesis: a mouse model of oral cavity squamous cell carcinoma. *Head Neck*, 16: 424–432, 1994.
- Phillips, D. H. Smoking-related DNA and protein adducts in human tissues. *Carcinogenesis (Lond.)*, 23: 1979–2004, 2002.
- Panigrahi, G. B., and Walker, I. G. The N2-guanine adduct, but not the C8-guanine or N6-adenine adducts formed by 4-nitroquinoline 1-oxide, blocks the 3'-5' exonuclease action of T4 DNA polymerase. *Biochemistry*, 29: 2122–2126, 1990.
- Thomas, D. C., Husain, I., Chaney, S. G., Panigrahi, G. B., and Walker, I. G. Sequence effect on incision by (A)BC exonuclease of 4NQO adducts and UV photoproducts. *Nucleic Acids Res.*, 19: 365–370, 1991.
- Venkat, J. A., Shami, S., Davis, K., Nayak, M., Plimmer, J. R., Pfeil, R., and Nair, P. P. Relative genotoxic activities of pesticides evaluated by a modified SOS microplate assay. *Environ. Mol. Mutagen.*, 25: 67–76, 1995.
- Ramotar, D., Belanger, E., Brodeur, I., Masson, J. Y., and Drobnetsky, E. A. A yeast homologue of the human phosphotyrosyl phosphatase activator PTPA is implicated in protection against oxidative DNA damage induced by the model carcinogen 4-nitroquinoline 1-oxide. *J. Biol. Chem.*, 273: 21489–21496, 1998.
- Kranendonk, M., Pintado, F., Mesquita, P., Laires, A., Vermeulen, N. P., and Rueff, J. MX100, a new *Escherichia coli* tester strain for use in genotoxicity studies. *Mutagenesis*, 11: 327–333, 1996.
- Tanuma, J., Shisa, H., Hiai, H., Higashi, S., Yamada, Y., Kamoto, T., Hirayama, Y., Matsuuchi, H., and Kitano, M. Quantitative trait loci affecting 4-nitroquinoline 1-oxide-induced tongue carcinogenesis in the rat. *Cancer Res.*, 58: 1660–1664, 1998.
- Steidler, N. E., and Reid, P. C. Experimental induction of oral squamous cell carcinomas in mice with 4-nitroquinoline-1-oxide. *Oral Surg.*, 57: 424–431, 1984.
- Yuan, B., Heniford, B. W., Ackermann, D. M., Hawkins, B. L., and Hendler, F. J. Harvey *ras* (H-*ras*) point mutations are induced by 4-nitroquinoline-1-oxide in murine oral squamous epithelia, while squamous cell carcinomas and loss of heterozygosity occur without additional exposure. *Cancer Res.*, 54: 5310–5317, 1994.
- Tanaka, T., Kojima, T., Hara, A., Sawada, H., and Mori, H. Chemoprevention of oral carcinogenesis by DL- α -difluoromethylornithine, an ornithine decarboxylase inhibitor dose dependent reduction in 4-nitroquinoline-1-oxide induced tongue neoplasms in rats. *Cancer Res.*, 53: 772–776, 1993.
- Nishimura, A. Changes in Bcl-2 and Bax expression in rat tongue during 4-nitroquinoline 1-oxide-induced carcinogenesis. *J. Dent. Res.*, 78: 1264–1269, 1999.
- Shiotani, H., Denda, A., Yamamoto, K., Kitayama, W., Endoh, T., Sasaki, Y., Tsutsumi, N., Sugimura, M., and Konishi, Y. Increased expression of cyclooxygenase-2 protein in 4-nitroquinoline-1-oxide-induced rat tongue carcinomas and chemopreventive efficacy of a specific inhibitor, nimesulide. *Cancer Res.*, 61: 1451–1456, 2001.

24. Tanaka, T., Kohno, H., Nomura, E., Taniguchi, H., Tsuno, T., and Tsuda, H. A novel geranylated derivative, ethyl 3-(4'-geranyloxy-3'-methoxyphenyl)-2-propenoate, synthesized from ferulic acid suppresses carcinogenesis and inducible nitric oxide synthase in rat tongue. *Oncology (Basel)*, **64**: 166–175, 2003.
25. Tanaka, T., Kohno, H., Sakata, K., Yamada, Y., Hirose, Y., Sugie, S., and Mori, H. Modifying effects of dietary capsaicin and rotenone on 4-nitroquinoline 1-oxide-induced rat tongue carcinogenesis. *Carcinogenesis (Lond.)*, **23**: 1361–1367, 2002.
26. Tanaka, T., Makita, H., Ohnishi, M., Mori, H., Satoh, K., and Hara, A. Chemoprevention of rat oral carcinogenesis by naturally occurring xanthophylls, astaxanthin and canthaxanthin. *Cancer Res.*, **55**: 4059–4064, 1995.
27. Rubin, J. S., Qiu, L., and Etkind, P. Amplification of the Int-2 gene in head and neck squamous cell carcinoma. *J. Laryngol. Otol.*, **109**: 72–76, 1995.
28. Serewko, M. M., Popa, C., Dahler, A. L., Smith, L., Strutton, G. M., Coman, W., Dicker, A. J., and Saunders, N. A. Alterations in gene expression and activity during squamous cell carcinoma development. *Cancer Res.*, **62**: 3759–3765, 2002.
29. Opitz, O. G., Harada, H., Suliman, Y., Rhoades, B., Sharpless, N. E., Kent, R., Kopelovich, L., Nakagawa, H., and Rustgi, A. K. A mouse model of human oral-esophageal cancer. *J. Clin. Investig.*, **110**: 761–769, 2002.
30. Lippman, S. M., and Hong, W. K. Molecular markers of the risk of oral cancer. *N. Engl. J. Med.*, **344**: 1323–1326, 2001.
31. Quon, H., Liu, F. F., and Cummings, B. J. Potential molecular prognostic markers in head and neck squamous cell carcinomas. *Head Neck*, **23**: 147–159, 2001.
32. Jemal, A., Murray, T., Samuels, A., Ghafoor, A., Ward, E., and Thun, M. J. Cancer statistics, 2003. *CA Cancer J. Clin.*, **53**: 5–26, 2003.
33. Wang, Z. Y., Wang, L. D., Lee, M. J., Ho, C. T., Huang, M. T., Conney, A. H., and Yang, C. S. Inhibition of N-nitrosomethylbenzylamine-induced esophageal tumorigenesis in rats by green and black tea. *Carcinogenesis*, **16**: 2143–2148, 1995.
34. Wargovich, M. J., and Imada, O. Esophageal carcinogenesis in the rat: a model for aerodigestive tract cancer. *J. Cell. Biochem.*, **17F** (Suppl.): 91–94, 1993.
35. Beer, D. G., and Stoner, G. D. Clinical models of chemoprevention for the esophagus. *Hematol. Oncol. Clin. N. Am.*, **12**: 1055–1077, 1998.
36. Song, J. I., and Grandis, J. R. STAT signaling in head and neck cancer. *Oncogene*, **19**: 2489–2495, 2000.
37. Papadimitrakopoulou, V. A., Clayman, G. L., Shin, D. M., Myers, J. N., Gillenwater, A. M., Goepfert, H., El-Naggar, A. K., Lewin, J. S., Lippman, S. M., and Hong, W. K. Biochemoprevention for dysplastic lesions of the upper aerodigestive tract. *Arch. Otolaryngol. Head Neck Surg.*, **125**: 1083–1089, 1999.
38. Sidransky, D. Emerging molecular markers of cancer. *Nat. Rev. Cancer*, **2**: 210–219, 2002.
39. Fong, L. Y., Ishii, H., Nguyen, V. T., Vecchione, A., Farber, J. L., Croce, C. M., and Huebner, K. p53 deficiency accelerates induction and progression of esophageal and forestomach tumors in zinc-deficient mice. *Cancer Res.*, **63**: 186–195, 2003.
40. Fuchs, E., and Weber, K. Intermediate filaments: structure, dynamics, function, and disease. *Annu. Rev. Biochem.*, **63**: 345–382, 1994.
41. Wong, P., Colucci-Guyon, E., Takahashi, K., Gu, C., Babinet, C., and Coulombe, P. A. Introducing a null mutation in the mouse K6 α and K6 β genes reveals their essential structural role in the oral mucosa. *J. Cell Biol.*, **150**: 921–928, 2000.
42. Fuchs, E., and Green, H. Changes in keratin gene expression during terminal differentiation of the keratinocyte. *Cell*, **19**: 1033–1042, 1980.
43. Kannan, S., Balaran, P., Chandran, G. J., Pillai, M. R., Mathew, B., Nalinakumari, K. R., and Nair, M. K. Differential expression of cytokeratin proteins during tumour progression in oral mucosa. *Epithelial Cell Biol.*, **3**: 61–69, 1994.
44. Cintorino, M., Tripod, S. A., Santopietro, R., Antonio, P., Lutfi, A., Chang, F., Syrjanen, S., Shen, Q., Tosi, P., and Syrjanen, K. Cytokeratin expression patterns as an indicator of tumour progression in oesophageal squamous cell carcinoma. *Anticancer Res.*, **21**: 4195–4201, 2001.
45. Chu, P. G., Lyda, M. H., and Weiss, L. M. Cytokeratin 14 expression in epithelial neoplasms: a survey of 435 cases with emphasis on its value in differentiating squamous cell carcinomas from other epithelial tumours. *Histopathol.*, **39**: 9–16, 2001.
46. Bloor, B. K., Seddon, S. V., and Morgan, P. R. Gene expression of differentiation specific keratins in oral epithelial dysplasia and squamous cell carcinoma. *Oral Oncol.*, **37**: 251–261, 2001.
47. Sherr, C. J., and Roberts, J. M. CDK inhibitors: positive and negative regulators of G₁-phase progression. *Genes Dev.*, **13**: 1501–1512, 1999.
48. Kamb, A. Cell-cycle regulators and cancer. *Trends Genet.*, **11**: 136–140, 1995.
49. Coleman, K. G., Wautlet, B. S., Morrissey, D., Mulheron, J., Sedman, S. A., Brinkley, P., Price, S., and Webster, K. R. Identification of CDK4 sequences involved in cyclin D1 and p16 binding. *J. Biol. Chem.*, **272**: 18869–18874, 1997.
50. Morisaki, H., Ando, A., Nagata, Y., Pereira-Smith, O., Smith, J. R., Ikeda, K., and Nakanishi, M. Complex mechanisms underlying impaired activation of Cdk4 and Cdk2 in replicative senescence: roles of p16, p21, and cyclin D1. *Exp. Cell Res.*, **253**: 503–510, 1999.
51. Tokugawa, T., Sugihara, H., Tani, T., and Hattori, T. Modes of silencing of p16 in development of esophageal squamous cell carcinoma. *Cancer Res.*, **62**: 4938–4944, 2002.
52. Todd, R., Hinds, P. W., Munger, K., Rustgi, A. K., Opitz, O. G., Suliman, Y., and Wong, D. T. Cell cycle dysregulation in oral cancer. *Crit. Rev. Oral Biol. Med.*, **13**: 51–61, 2002.
53. Papadimitrakopoulou, V., Izzo, J., Lippman, S. M., Lee, J. S., Fan, Y. H., Clayman, G., Ro, J. Y., Hittelman, W. N., Lotan, R., Hong, W. K., and Mao, L. Frequent inactivation of p16INK4a in oral premalignant lesions. *Oncogene*, **14**: 1799–1803, 1997.
54. Kresty, L. A., Mallory, S. R., Knobloch, T. J., Song, H., Lloyd, M., Casto, B. C., and Weghorst, C. M. Alterations of p16^{INK4a} and p14^{ARF} in patients with severe oral epithelial dysplasia. *Cancer Res.*, **62**: 5295–5300, 2002.
55. Riese, U., Dahse, R., Fiedler, W., Theuer, C., Koscielny, S., Ernst, G., Beleites, E., Claussen, U., and von Eggeling, F. Tumor suppressor gene p16 (CDKN2A) mutation status and promoter inactivation in head and neck cancer. *Int. J. Mol. Med.*, **4**: 61–65, 1999.
56. Nakahara, Y., Shintani, S., Mihara, M., Kiyota, A., Ueyama, Y., and Matsumura, T. Alterations of Rb, p16^{INK4a} and cyclin D1 in the tumorigenesis of oral squamous cell carcinomas. *Cancer Lett.*, **160**: 3–8, 2000.
57. Namazie, A., Alavi, S., Olopade, O. I., Pauletti, G., Aghamohammadi, N., Aghamohammadi, M., Gornbein, J. A., Calcaterra, T. C., Slamon, D. J., Wang, M. B., and Srivatsan, E. S. Cyclin D1 amplification and p16(MTS1/CDK4I) deletion correlate with poor prognosis in head and neck tumors. *Laryngoscope*, **112**: 472–481, 2002.
58. Hasegawa, M., Nelson, H. H., Peters, E., Ringstrom, E., Posner, M., and Kelsey, K. T. Patterns of gene promoter methylation in squamous cell cancer of the head and neck. *Oncogene*, **21**: 4231–4236, 2002.
59. Ambrosch, P., Schlott, T., Hilmes, D., and Ruschenburg, I. p16 alterations and retinoblastoma protein expression in squamous cell carcinoma and neighboring dysplasia from the upper aerodigestive tract. *Virchows Arch.*, **438**: 343–349, 2001.
60. Boni-Schnetzler, M., and Pilch, P. F. Mechanism of epidermal growth factor receptor autophosphorylation and high-affinity binding. *Proc. Natl. Acad. Sci. USA*, **84**: 7832–7836, 1987.
61. Barnard, J. A., Graves-Deal, R., Pittelkow, M. R., DuBois, R., Cook, P., Ramsey, G. W., Bishop, P. R., Damstrup, L., and Coffey, R. J. Auto- and cross-induction within the mammalian epidermal growth factor-related peptide family. *J. Biol. Chem.*, **269**: 22817–22822, 1994.
62. Hanahan, D., and Weinberg, R. A. The hallmarks of cancer. *Cell*, **100**: 57–70, 2000.
63. Kim, E. S., Khuri, F. R., and Herbst, R. S. Epidermal growth factor receptor biology (IMC-C225). *Curr. Opin. Oncol.*, **13**: 506–513, 2001.

64. Mendelsohn, J., and Baselga, J. The EGF receptor family as targets for cancer therapy. *Oncogene*, 19: 6550–6565, 2000.
65. Ciardiello, F., and Tortora, G. A novel approach in the treatment of cancer: targeting the epidermal growth factor receptor. *Clin. Cancer Res.*, 7: 2958–2970, 2001.
66. Shin, D. M., Ro, J. Y., Hong, W. K., and Hittelman, W. N. Dysregulation of epidermal growth factor receptor expression in premalignant lesions during head and neck tumorigenesis. *Cancer Res.*, 54: 3153–3159, 1994.
67. Grandis, J. R., and Twardy, D. J. Elevated levels of transforming growth factor α and epidermal growth factor receptor messenger RNA are early markers of carcinogenesis in head and neck cancer. *Cancer Res.*, 53: 3579–3584, 1993.
68. Issing, W. J., Wustrow, T. P., and Heppt, W. J. Oncogenes related to head and neck cancer. *Anticancer Res.*, 13: 2541–2551, 1993.
69. Grandis, J. R., Twardy, D. J., and Melhem, M. F. Asynchronous modulation of transforming growth factor α and epidermal growth factor receptor protein expression in progression of premalignant lesions to head and neck squamous cell carcinoma. *Clin. Cancer Res.*, 4: 13–20, 1998.
70. Grandis, J. R., Melhem, M. F., Gooding, W. E., Day, R., Holst, V. A., Wagener, M. M., Drenning, S. D., and Twardy, D. J. Levels of TGF- α and EGFR protein in head and neck squamous cell carcinoma and patient survival. *J. Natl. Cancer Inst. (Bethesda)*, 90: 824–832, 1998.
71. Todd, R., and Wong, D. T. Epidermal growth factor receptor (EGFR) biology and human oral cancer. *Histol. Histopathol.*, 14: 491–500, 1999.
72. Friess, H., Fukuda, A., Tang, W. H., Eichenberger, A., Furlan, N., Zimmermann, A., Korc, M., and Buchler, M. W. Concomitant analysis of the epidermal growth factor receptor family in esophageal cancer: overexpression of epidermal growth factor receptor mRNA but not of c-erbB-2 and c-erbB-3. *World J. Surg.*, 23: 1010–1018, 1999.
73. Ellwart, J., and Dormer, P. Effect of 5-fluoro-2'-deoxyuridine (FdUrd) on 5-bromo-2'-deoxyuridine (BrdUrd) incorporation into DNA measured with a monoclonal BrdUrd antibody and by the BrdUrd/Hoechst quenching effect. *Cytometry*, 6: 513–520, 1985.
74. von Pressentin, M. M., Kosinska, W., and Guttenplan, J. B. Mutagenesis induced by oral carcinogens in lacZ mouse (MutaMouse) tongue and other oral tissues. *Carcinogenesis (Lond.)*, 20: 2167–2170, 1999.
75. Ide, F., Oda, H., Nakatsuru, Y., Kusama, K., Sakashita, H., Tanaka, K., and Ishikawa, T. Xeroderma pigmentosum group A gene action as a protection factor against 4-nitroquinoline 1-oxide-induced tongue carcinogenesis. *Carcinogenesis (Lond.)*, 22: 567–572, 2001.
76. von Pressentin, M. M., El-Bayoumy, K., and Guttenplan, J. B. Mutagenic activity of 4-nitroquinoline-N-oxide in upper aerodigestive tissue in lacZ mice (MutaMouse) and the effects of 1,4-phenylenebis-(methylene)selenocyanate. *Mutat. Res.*, 466: 71–78, 2000.
77. Lindberg, K., and Rheinwald, J. G. Suprabasal 40 kd keratin (K19) expression as an immunohistologic marker of premalignancy in oral epithelium. *Am. J. Pathol.*, 134: 89–98, 1989.
78. Viaene, A. L., and Baert, J. H. Expression of cytokeratin-mRNAs in squamous-cell carcinoma and balloon-cell formation of human oesophageal epithelium. *Histochem. J.*, 27: 69–78, 1995.
79. Wu, C. L., Roz, L., McKown, S., Sloan, P., Read, A. P., Holland, S., Porter, S., Scully, C., Paterson, I., Tavassoli, M., and Thakker, N. DNA studies underestimate the major role of CDKN2A inactivation in oral and oropharyngeal squamous cell carcinomas. *Genes Chromosomes Cancer*, 25: 16–25, 1999.
80. Lai, S., and El-Naggar, A. K. Differential expression of key cell cycle genes (p16/cyclin D1/pRb) in head and neck squamous carcinomas. *Lab. Invest.*, 79: 255–260, 1999.
81. Rubin Grandis, J., Chakraborty, A., Melhem, M. F., Zeng, Q., and Twardy, D. J. Inhibition of epidermal growth factor receptor gene expression and function decreases proliferation of head and neck squamous carcinoma but not normal mucosal epithelial cells. *Oncogene*, 15: 409–416, 1997.
82. Lango, M., Wentzel, A. L., Song, J. I., Xi, S., Johnson, D. E., Lamph, W. W., Miller, L., and Grandis, J. R. Responsiveness to the retinoic acid receptor-selective retinoid LGD1550 correlates with abrogation of transforming growth factor α /epidermal growth factor receptor autocrine signaling in head and neck squamous carcinoma cells. *Clin. Cancer Res.*, 9: 4205–4213, 2003.
83. Holsinger, F. C., Doan, D. D., Jasser, S. A., Swan, E. A., Greenberg, J. S., Schiff, B. A., Bekele, B. N., Younes, M. N., Bucana, C. D., Fidler, I. J., and Myers, J. N. Epidermal growth factor receptor blockade potentiates apoptosis mediated by paclitaxel and leads to prolonged survival in a murine model of oral cancer. *Clin. Cancer Res.*, 9: 3183–3189, 2003.
84. Uhlman, D. L., Adams, G., Knapp, D., Aeppli, D. M., and Niehans, G. Immunohistochemical staining for markers of future neoplastic progression in the larynx. *Cancer Res.*, 56: 2199–2205, 1996.